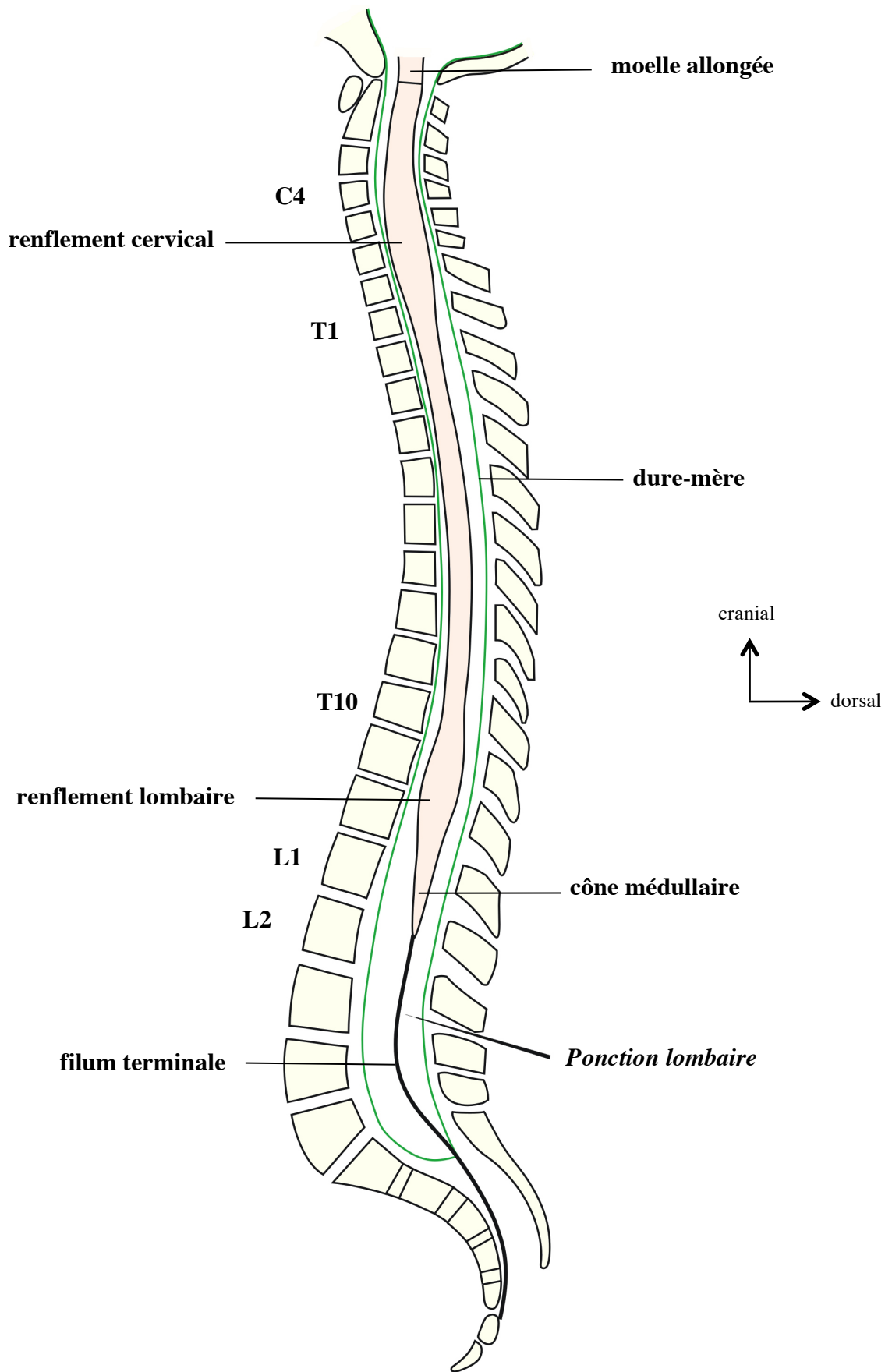
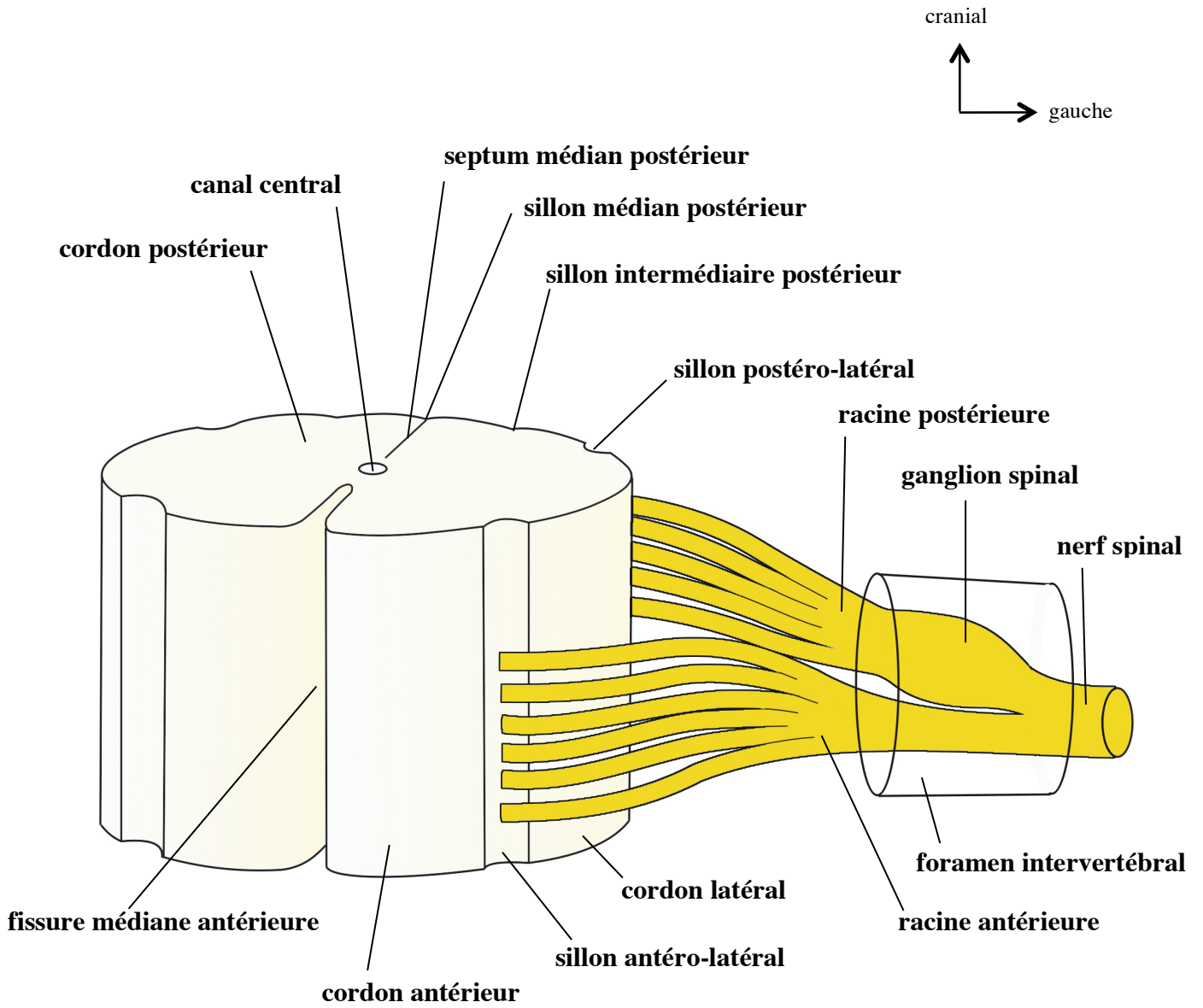


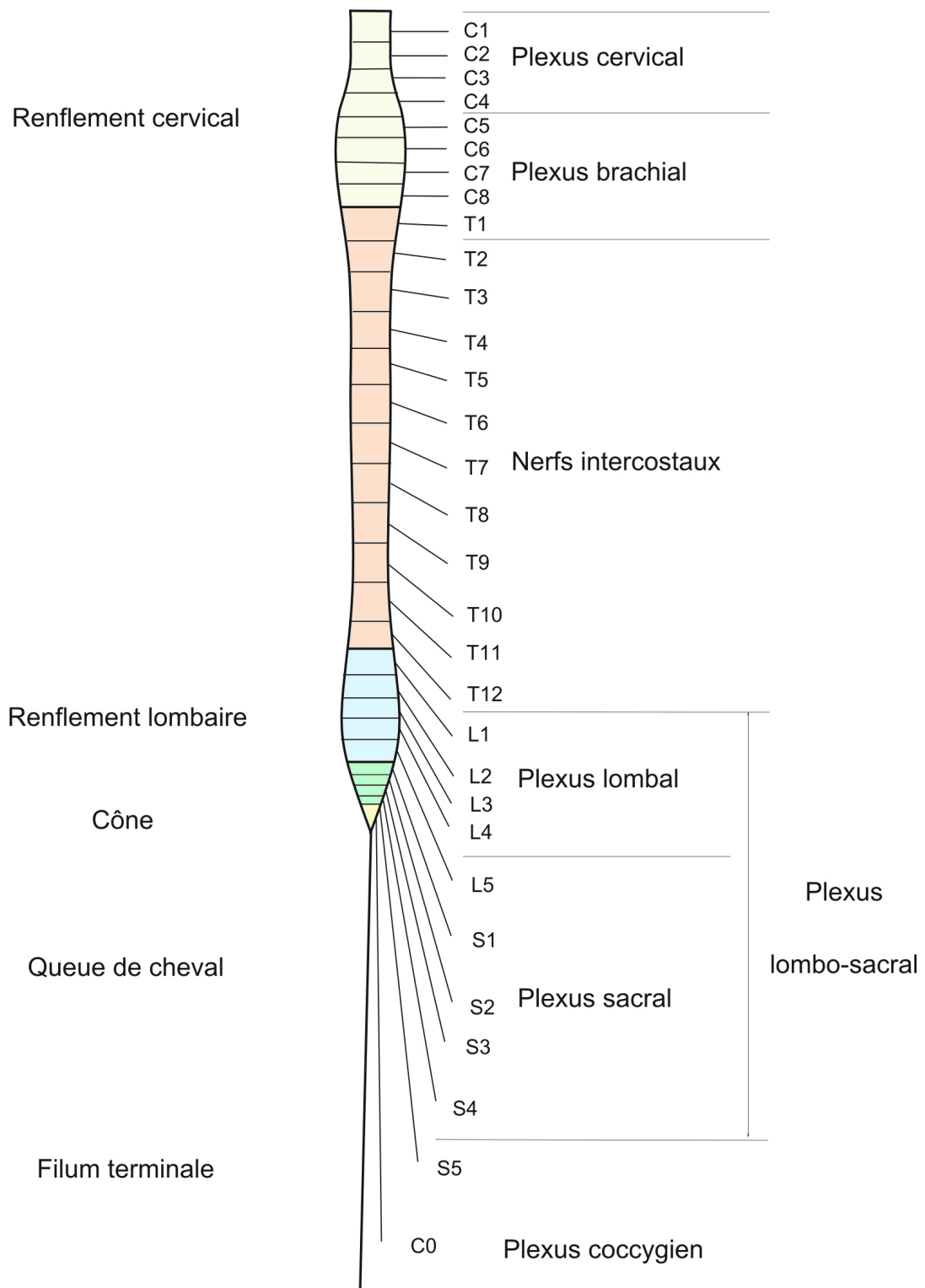
LA MOELLE SPINALE



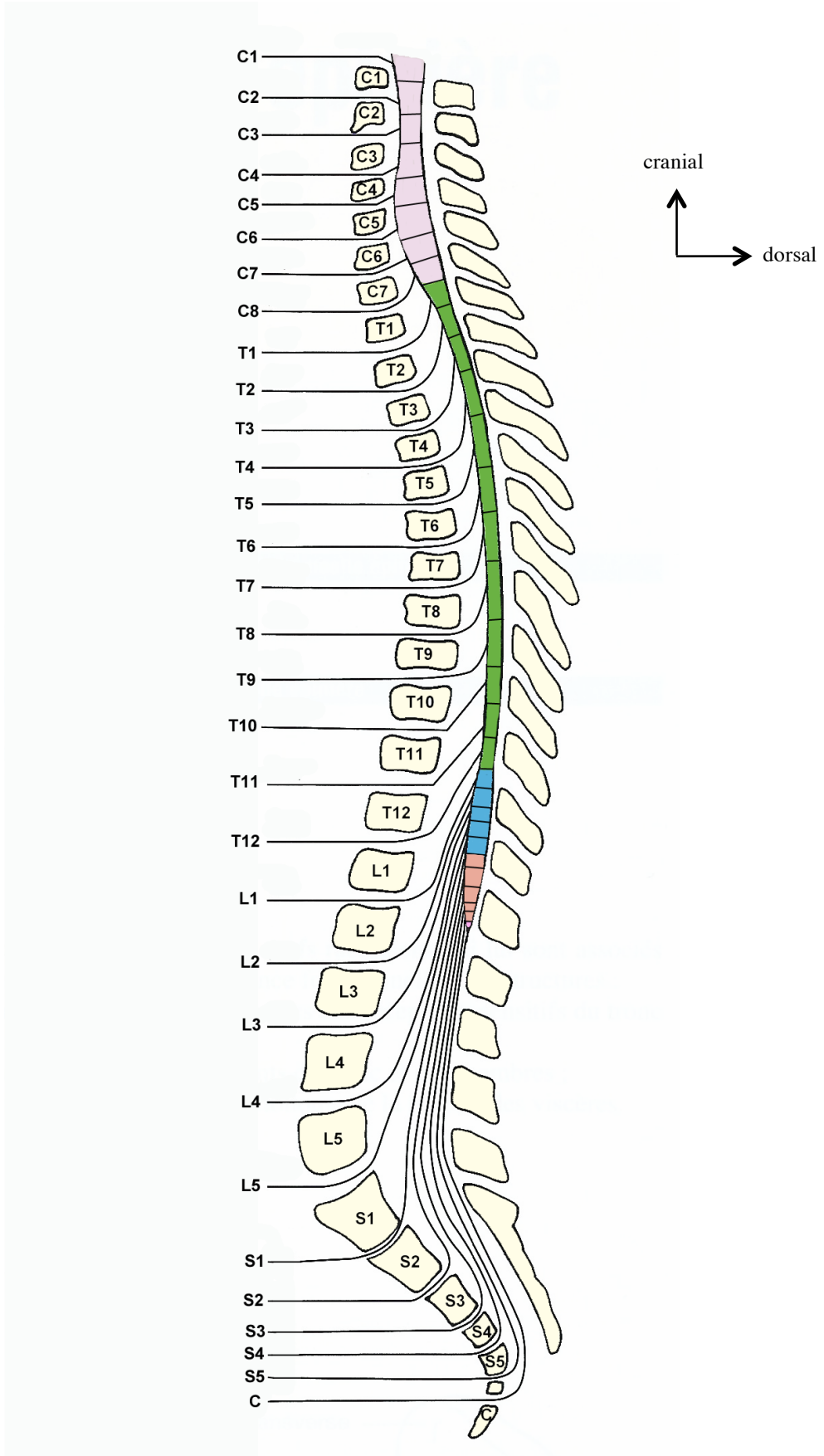
Vue latérale de la moelle



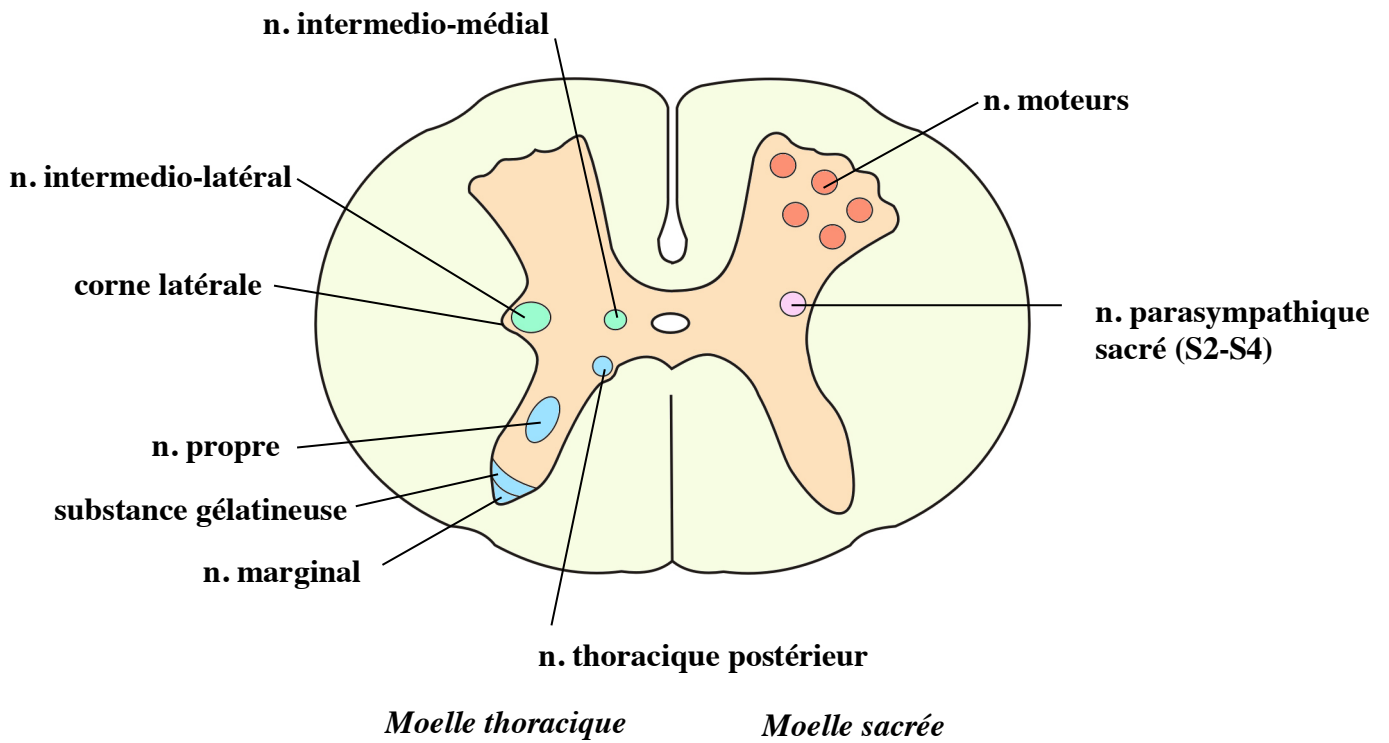
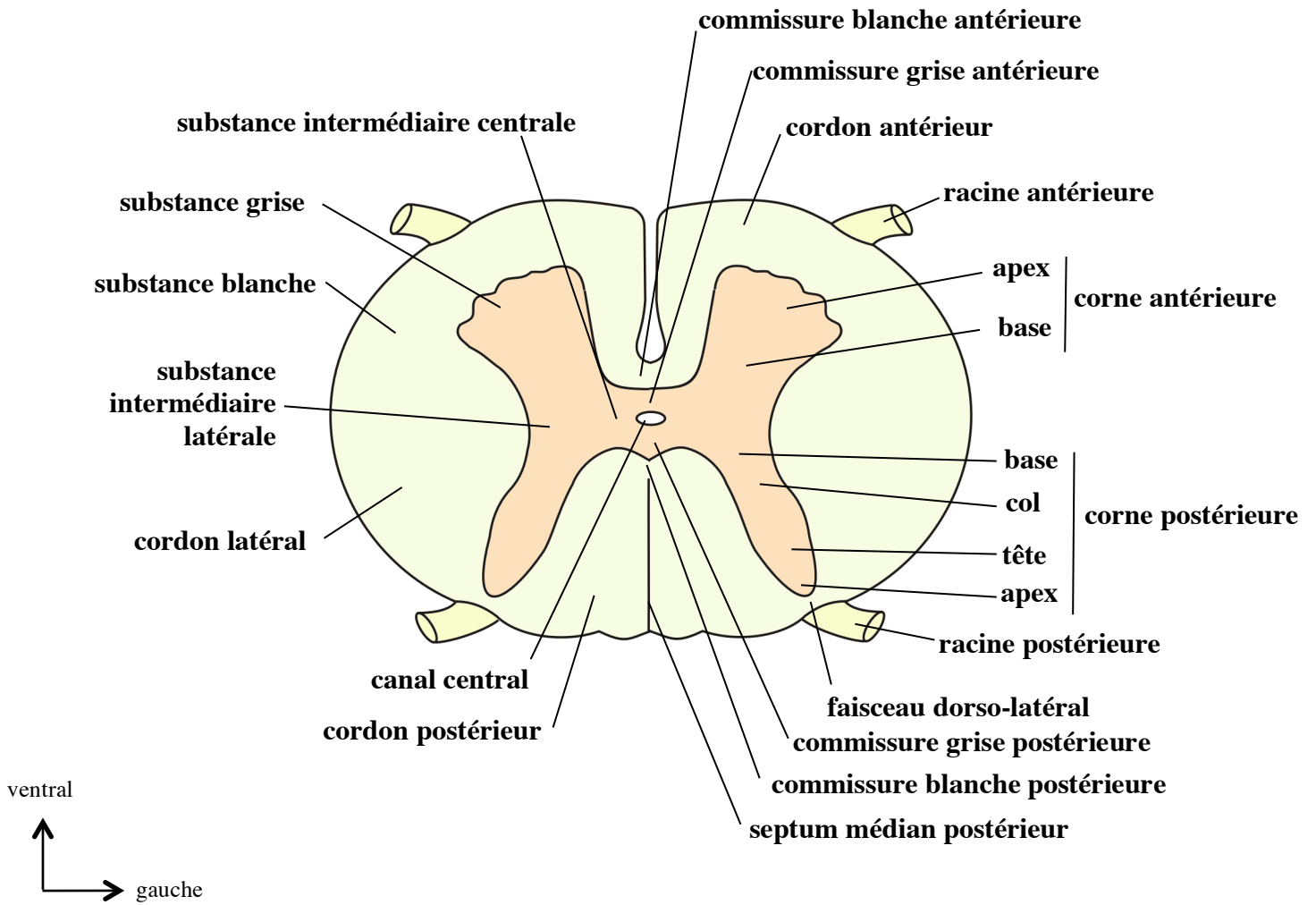
Vue antéro-latérale d'un segment de moelle



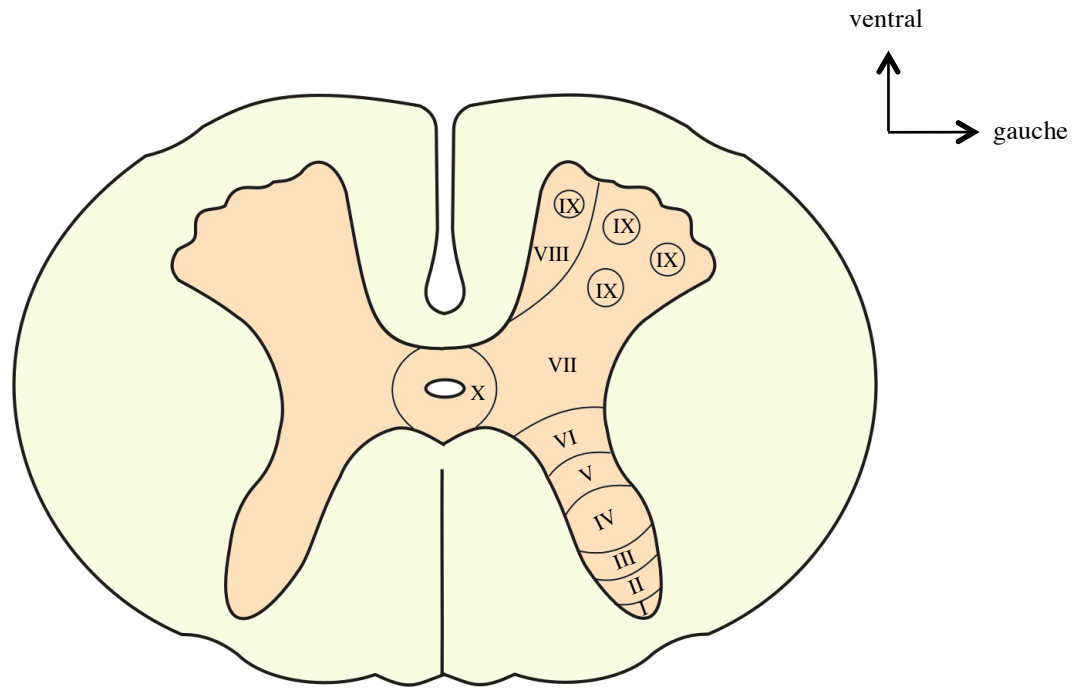
**Les segments médullaires et les nerfs spinaux
(vue ventrale)**



Les segments médullaires, les nerfs spinaux et les rapports vertébraux

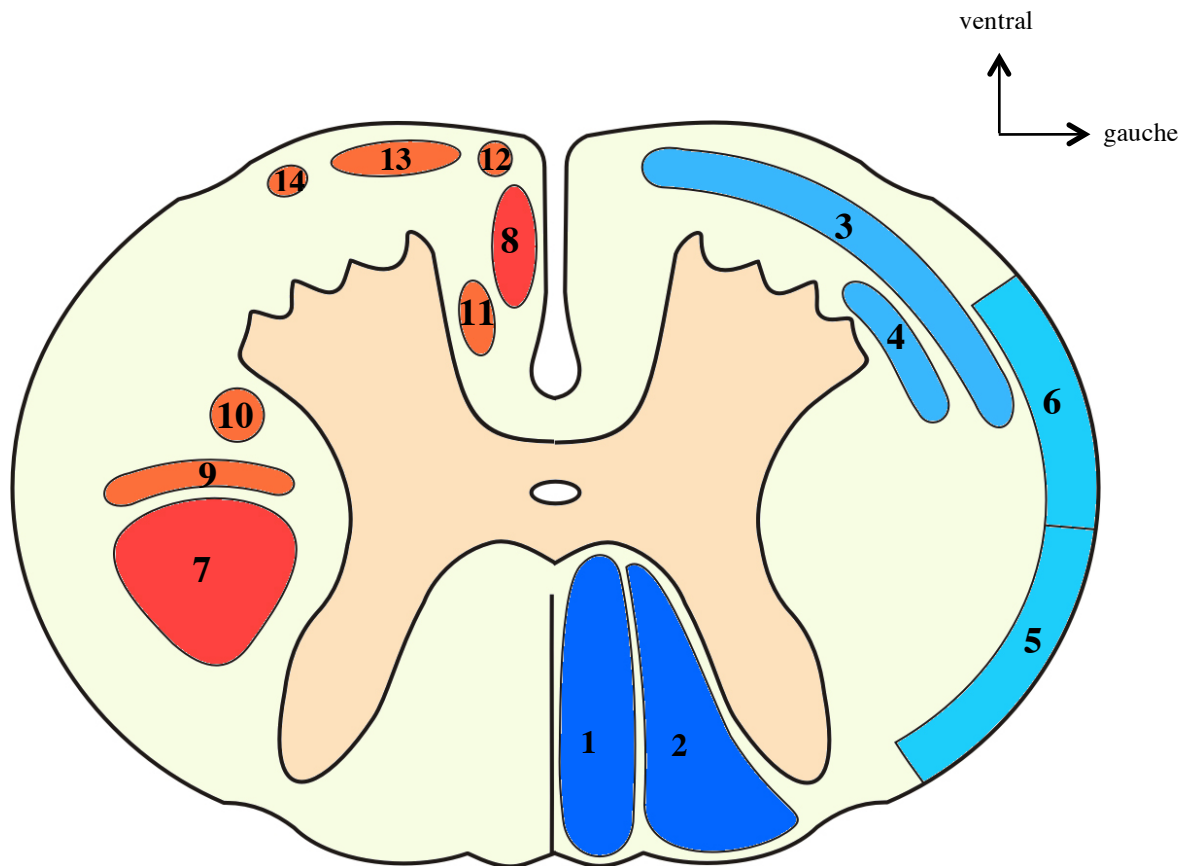


Structure de la moelle (coupe horizontale)



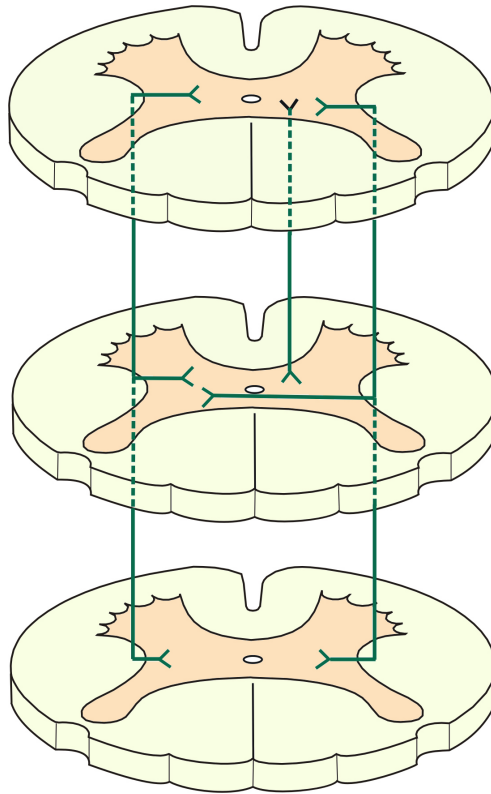
Corne postérieure	Apex	Noyau marginal	Lame I
	Tête	Substance gélatineuse	Lame II
	Col	Noyau propre	Lame III
			Lame IV
Base		Lame V	
Substance intermédiaire latérale			Lame VII
Substance intermédiaire centrale			Lame X
Corne antérieure			Lame VIII
			Lame IX

Les lames de Rexed

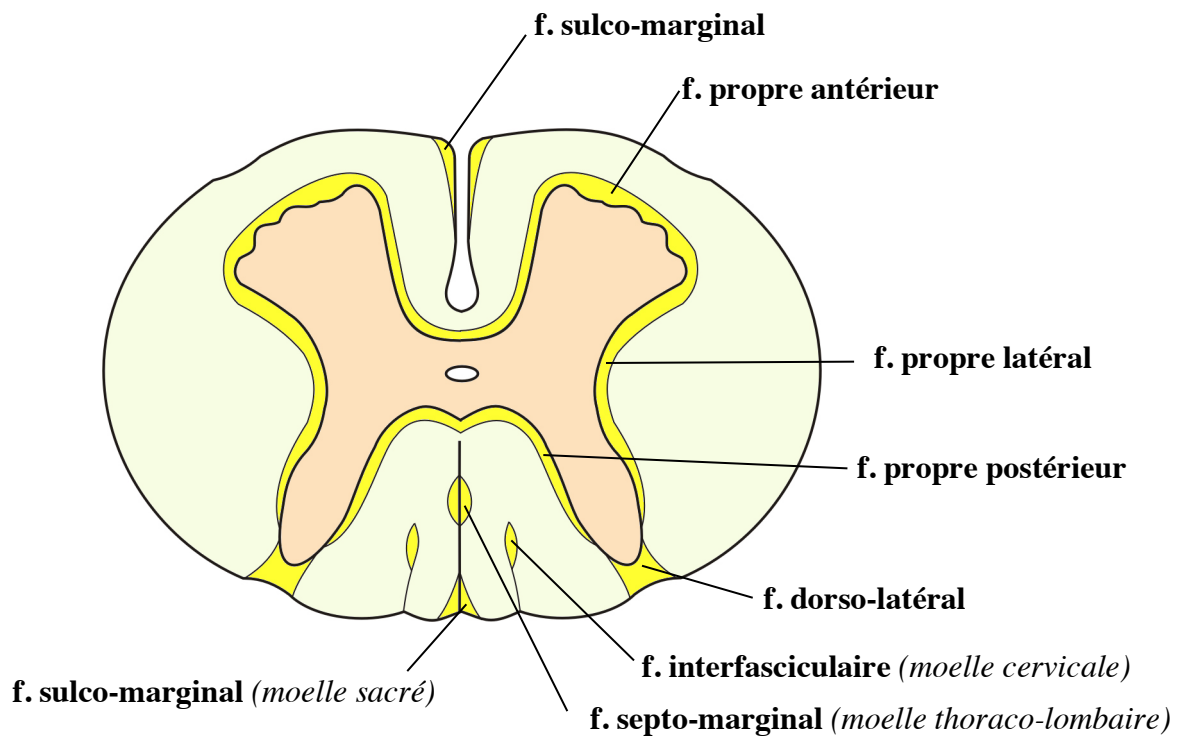


1	Faisceau gracile
2	Faisceau cunéiforme
3	Tractus néo-spino-thalamique
4	Tractus paléo-spino-réticulo-thalamique
5	Tractus spino-cérébelleux postérieur
6	Tractus spino-cérébelleux antérieur
7	Tractus cortico-spinal latéral
8	Tractus cortico-spinal antérieur
9	Tractus rubro-spinal
10	Tractus réticulo-spinal latéral
11	Tractus réticulo-spinal antérieur (médial)
12	Tractus tecto-spinal
13	Tractus vestibulo-spinal
14	Tractus olivo-spinal et spino-olivaire

**La substance blanche de la moelle - Principaux faisceaux
(coupe horizontale schématique)**

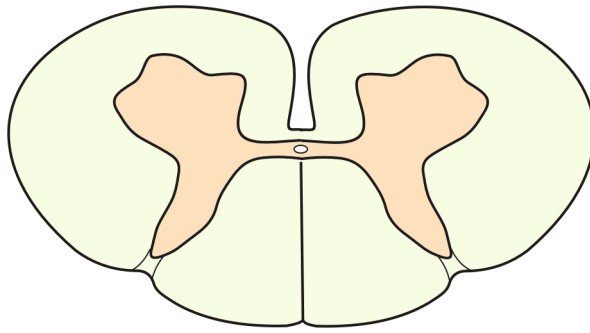


ventral
 ↑
 gauche →

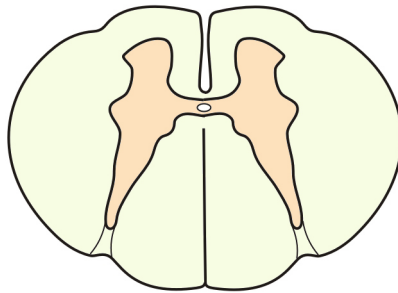


Les faisceaux d'association

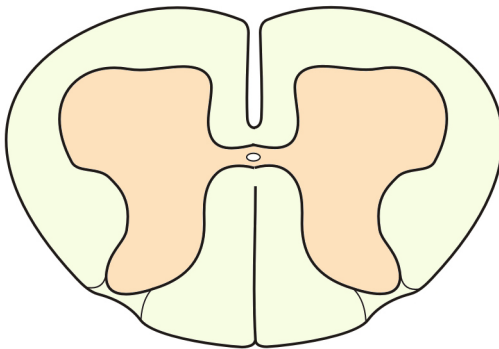
ventral
↑
gauche →



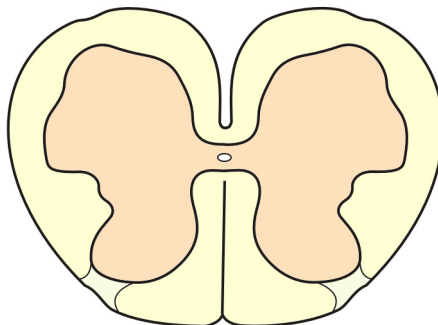
Moelle cervicale



Moelle thoracique

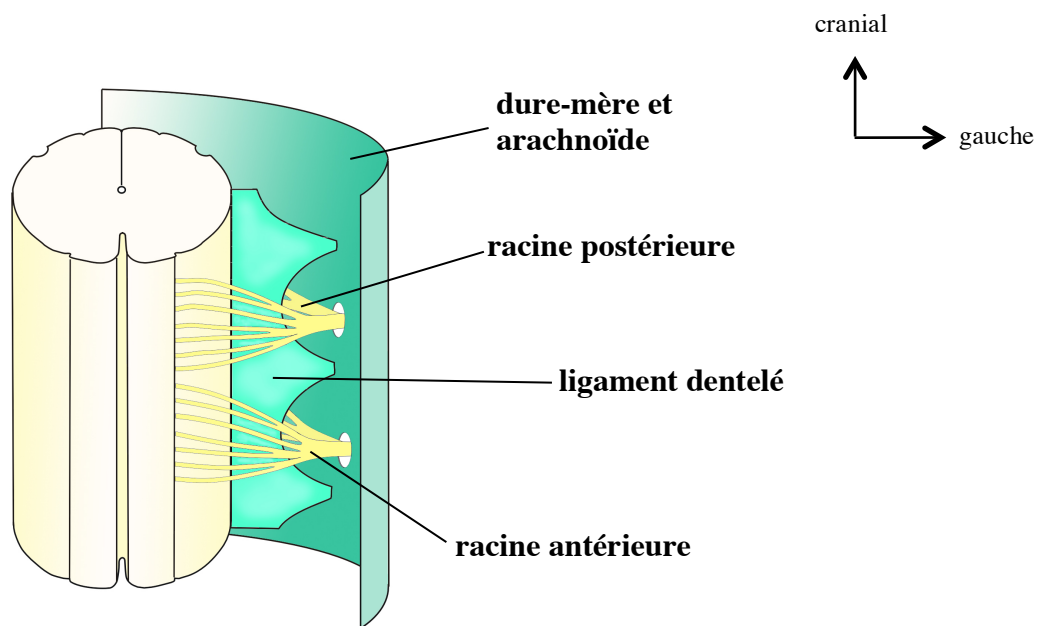
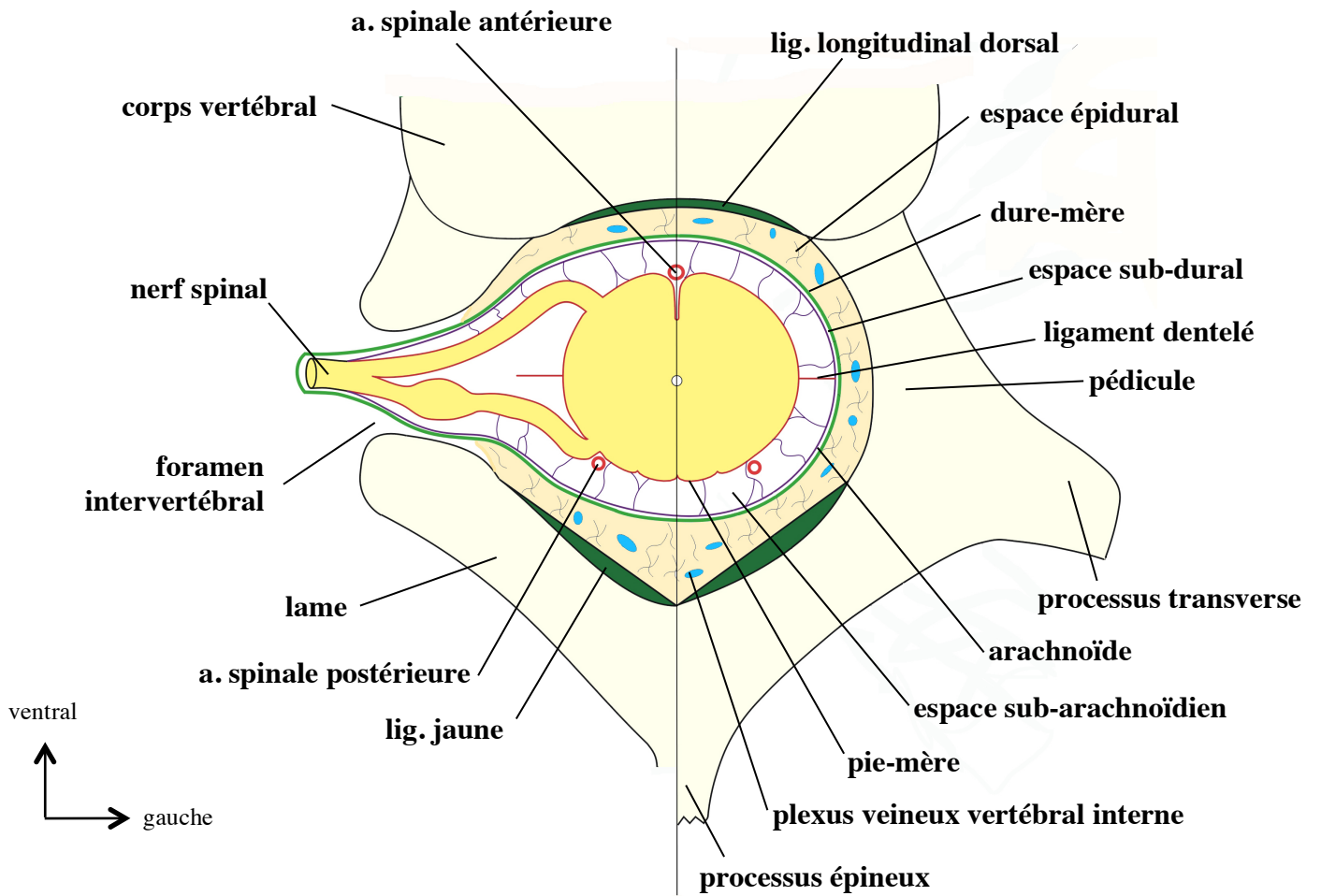


Moelle lombaire



Moelle sacrée

Variation de structure de la moelle en fonction des niveaux



Rapports de la moelle